

R. Luchetti<sup>1</sup>  
M. Riccio<sup>2</sup>  
I. Papini Zorli<sup>1</sup>  
T. Fairplay<sup>3</sup>

## Protective Coverage of the Median Nerve Using Fascial, Fasciocutaneous or Island Flaps

*Weichteildeckung des N. medianus durch Faszien-, Fasziokutane- und Insel-Lappenplastiken*

### Abstract

**Purpose:** The aim of the study is to present our experience with fascial or fasciocutaneous pedicle and island flaps in the treatment of recurrences of CTS with and without median nerve lesions. **Material and Methods:** From 1987 to 2006 we have operated on 25 patients (17 women and 8 men, ages ranging from 38 to 76 years with a mean age of 55 years) due to a recurrence of CTS. All the patients required nerve coverage using a local or distant flap. There were 19 hypothenar fat flaps; two forearm radial artery flaps, a forearm ulnar artery flap, an ulnar fascial-fat flap and a posterior interosseous flap. Patients were clinically and instrumentally evaluated before the operation. Assessments of the evaluation parameters were classified in excellent, good, fair and poor according to clinical and return to work criteria. **Results:** Patients were evaluated after a mean follow-up of 51 months (12 to 168 months). The pain evaluation showed an improvement passing from a mean value of 9 to 4. The best results were for those patients in whom the median nerve was undamaged (mean value of 1). Eleven patients obtained excellent results; good results were obtained in twelve cases; two patients demonstrated fair results due to partial median nerve injury. In these cases, a hypothenar fat flap and an ulnar fascial-fat flap were used, respectively. **Conclusion:** Protective coverage of the median nerve by using fascial or fasciocutaneous flaps after failure of CTR and/or unsuccessful re-operations is a good solution to furnish to the median nerve a gliding tissue to avoid adhesences with the surrounding tissue of previous surgery. The protection

### Zusammenfassung

**Ziel:** In der vorliegenden Studie sollen unsere Erfahrungen und Ergebnisse mit der Weichteildeckung des N. medianus nach Karpaldachspaltung mit oder ohne Nervenverletzungen durch Faszi-, Fasziokutane- oder Insel-Lappenplastiken zusammengefasst werden. **Patienten und Methoden:** Von 1987 bis 2006 wurden 25 Patienten (17 Frauen und 8 Männer mit einem mittleren Alter von 55 [38 bis 76] Jahren) wegen eines rezidivierenden Karpaltunnelsyndroms operativ behandelt. Alle Patienten wurden mit dem Ziel der Weichteildeckung des Nerven durch eine lokale oder regionale Lappenplastik behandelt. Zur Anwendung kamen die Hypothenar-Fett-Faszi-Lappenplastik (n = 19), die distal gestielte A. radialis-Lappenplastik (n = 2), die A. ulnaris-Lappenplastik (n = 1), die ulnarseitige Fett-Faszi-Lappenplastik (n = 1) sowie die A. interossea posterior-Lappenplastik (n = 1). Die Patienten wurden prä- und postoperativ untersucht. Die Ergebnisse wurden entsprechend der Evaluationskriterien in „sehr gut“, „gut“, „befriedigend“ und „schlecht“ eingestuft. **Ergebnisse:** Die Patienten wurden durchschnittlich 51 (12 bis 168) Monate nach der Operation untersucht. Die durchschnittliche Schmerzangabe (VAS) reduzierte sich von präoperativ 9 auf postoperativ 4. Die besten Ergebnisse wurden bei Patienten ohne zusätzliche Schädigung des N. medianus erzielt (durchschnittlicher Wert 1). Elf Patienten erreichten entsprechend der Kriterien ein sehr gutes Ergebnis und n = 12 ein gutes Ergebnis. In den zwei Fällen mit befriedigendem Ergebnis lag eine partielle Schädigung des N. medianus vor. In diesen Fällen war eine Hypothenar-Fett-Faszi-

### Institutsangaben

<sup>1</sup> Rimini Hand and Upper Extremities Centre, Rimini, Italy  
<sup>2</sup> Department of Hand Surgery, Clinic of Plastic and Reconstruction Surgery, University of Ancona, Torrette Hospital, Ancona, Italy  
<sup>3</sup> Rehabilitation Hand Centre, Private Centre, Bologna, Italy

### Korrespondenzadresse

Riccardo Luchetti, M.D. · Rimini Hand and Upper Extremities Centre · Via Pietro da Rimini 4 · 47900 Rimini · Italy · E-mail: rluc@adhoc.net

Eingang des Manuskriptes: 7.8.2006 · Angenommen: 10.8.2006

### Bibliografie

Handchir Mikrochir Plast Chir 2006; 38: 317–330 © Georg Thieme Verlag KG Stuttgart · New York · ISSN 0722-1819 · DOI 10.1055/s-2006-924551

of the nerve can reduce painful symptoms even if it does not permit a return to a painless condition. However, the clinical results in terms of median nerve functional recovery cannot be predicted: if the median nerve is damaged, protective coverage of it by flaps cannot give a favourable result in terms of recovery of both sensory and motor deficits.

### Key words

Recurrent carpal tunnel syndrome · recalcitrant CTS · fascial flap · fasciocutaneous flap · island flap

## Introduction

Recurrent carpal tunnel syndrome is a clinical problem that continues to be an on-going challenge for hand surgeons. It is a different entity with less favourable chances of success, both diagnostically and in its final treatment outcome when compared to primary carpal tunnel syndrome.

Results after secondary surgery depend on several factors ranging from the type of median nerve injury to the specific strategy chosen to address the problem [2,14]. Frequently, intra-operative findings consist of extensive fibrosis where the median nerve is scarred down to the flexor tendons or the roof of the tunnel [2,14]. This implies that its pathophysiology may be a consequence of poor nerve gliding and nerve compression, thus decreasing its vascularisation [14].

To create a barrier against adhesions, we have several so-called reconstructive ladder options that can be used, for example: local tissue, distant and pedicled tissue (e.g., posterior interosseous artery flap, reversed radial forearm flap) and free vascularised tissue [8]. Local tissue treatment examples of recurrent carpal tunnel syndrome include the palmaris brevis turn-over flap [16], the pedicled hypothenar fat flap [9,19], the synovial flap [22], and the abductor digiti minimi flap [17]. In addition, we may also make use of autologous tissue and allogenic absorbable barriers which also have been used to reduce the recurrence rate [11].

A recent study compared the coverage of the median nerve with free and pedicled flaps [6] and the authors of that study concluded that local vascularised tissue, preferably the ulnar-based fat flap, is quite worthwhile, rendering good results [6].

The goal of this study is to present our experience in the treatment of CTS recurrence, with and without median nerve lesions, using fascial or fasciocutaneous pedicle and island flaps.

Lappenplastik beziehungsweise eine ulnarseitige Fett-Faszien-Lappenplastik durchgeführt worden. **Schlussfolgerungen:** Die Weichteildeckung des N. medianus durch Faszien- oder Faszio-kutane-Lappenplastiken nach einer erfolglosen Karpaldachspaltung und/oder einer erfolglosen Revisionsoperation ermöglicht eine erfolgreiche Behandlung durch Bedeckung des N. medianus mit neuem Gleitgewebe. Dadurch können neue Vernarbungen mit dem umgebenden Narbengewebe vermieden werden. Die „Abpolsterung“ des N. medianus durch eine Lappenplastik erlaubt insgesamt eine deutliche Schmerzreduktion, auch wenn eine gewisse Schmerzsymptomatik zurückbleibt. Ein günstigeres Ergebnis für die funktionelle Erholung des Nervs hinsichtlich sensibler und motorischer Defizite bei direkten Schäden des N. medianus wird durch die Operation jedoch nicht erreicht.

### Schlüsselwörter

Karpaltunnelsyndrom · Rezidiv-Faszien-Lappenplastiken · Faszio-kutane-Lappenplastiken · Insel-Lappenplastiken

## Material and Methods

From 1987 to 2006 we have operated on 75 patients due to recurrence of CTS after open (CTR) or endoscopic (ECTR) treatment (ten cases). Patient inclusion criteria were based on those who had persistent, recurrent and new symptom onset according to the Mackinnon classification [1]. Patients who had undergone multiple CTS revision surgeries were also included in this study.

The majority of the 75 patients who were included in this study had undergone a simple flexor retinaculum release for incomplete CTR, but 25 of these patients required nerve coverage by using a local or distant flap. This study included 17 women and 8 men, ages ranging from 38 to 76 years with a mean age of 55 years.

Patients were clinically and instrumentally evaluated before the operation. Sensory and motor deficits were recorded using a hand-held dynamometer, the Semmes-Weinstein monofilament test and a two-point discrimination test, respectively. Pain was evaluated by using the visual analogue scale (VAS) from 0 (no pain) to 10 (maximum pain). Paraesthesia at the fingers, Tinel sign and Phalen test were all documented. Neurophysiological studies (VCS, VCM, EMG) were always performed and compared with the preoperative studies when available.

Assessments of the evaluation parameters were classified in excellent, good, fair and poor according to clinical and return to work criteria (Table 1).

Median nerve coverage indications were decided during the surgical course according to the presence and amount of perineurial fibrosis and nerve damage [15]. Indications for performing only the hypothenar fat flaps were decided if there was a limited amount of median nerve perineurial fibrosis without the presence of nerve damage.

Tab. 1 Scoring system of the result

<i>Excellent</i>	Complete relief of symptoms and a normal postoperative two-point discrimination value. The patients returned to their prior work level
<i>Good</i>	Symptomatic patient with long periods of well-being followed by a period of pain, but not severe enough to impede the full use of the hand. These patients suffered mild intermittent pain, numbness and/or scar tenderness
<i>Fair</i>	Pain and persistent paraesthesia but of a reduced intensity with respect to their preoperative symptoms
<i>Poor</i>	Unmodified or aggravated symptoms from the surgery

The fasciocutaneous flaps were used based on several indications: replacement of tenacious cutaneous scarring in the interthenar zone; the zone in which the median nerve had been damaged did not permit sufficient coverage by a fat-flap; broad amount of median nerve adhesences, concomitant partial median nerve injury or presence of a cutaneous palmar branch neuroma. The above-mentioned cases were associated with previous multiple surgeries.

Median nerve coverage procedures of choice are described in the following paragraphs.

## Technique

### Skin incision

The preferred approach to the median nerve is made 1–2 cm ulnarly in respect to the existing cutaneous scar incision [5, 7]. The skin is incised in the direction of the ring finger from the proximal palmar wrist flexion crease, continues along the ulnar side of the forearm. The median nerve neurolysis should begin at a point in which the nerve is not scarred and move towards the direction of the scarred down nerve (i.e., proximal to distal or vice versa) (Fig. 1a to c). After the nerve, together with its thenar branch, has been completely freed from the carpal tunnel scar tissue, the appropriate flap that should amply cover the nerve, is harvested from the wrist or the forearm.

A cutaneous incision can be made on the pre-existing scar, especially if the scar should be excised and replaced with a fasciocutaneous flap.

### Hypothenar fat-flap [9, 19]

The subcutaneous fatty tissue that is located immediately below the epidermis is dissected and moved in an ulnar direction up to the abductor digiti minimi fascia. The fat flap, including the palmaris brevis, is dissected in a radial direction up to Guyon's canal. The palmar branch of the ulnar nerve and its palmar digital nerves must be carefully preserved since the ulnar nerve and artery lie within Guyon's canal. It is of utmost importance to preserve the fine terminal branches of ulnar artery which ensure the blood supply to the flap. The flap dimensions are 4 × 3 cm and it is pedicled by the ulnar artery branches on its radial side, where it is bound like the page of a book, and can be used to cover the scarred region of the median nerve (Fig. 1d). The flap's ulnar side is then stitched with absorbable sutures to the radial wall of the carpal canal and anchored just below, but within, the

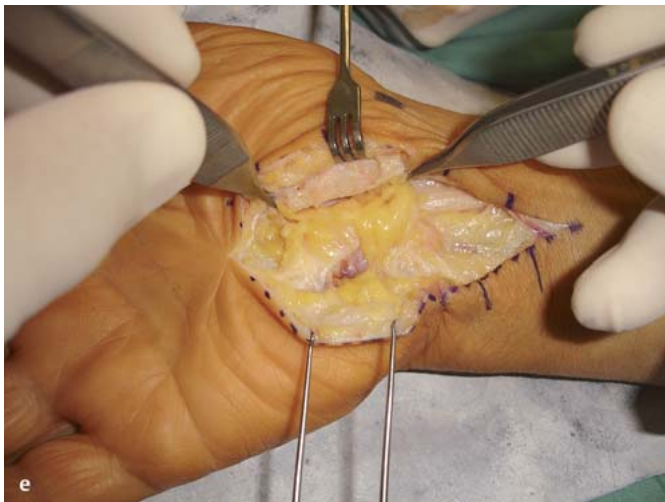
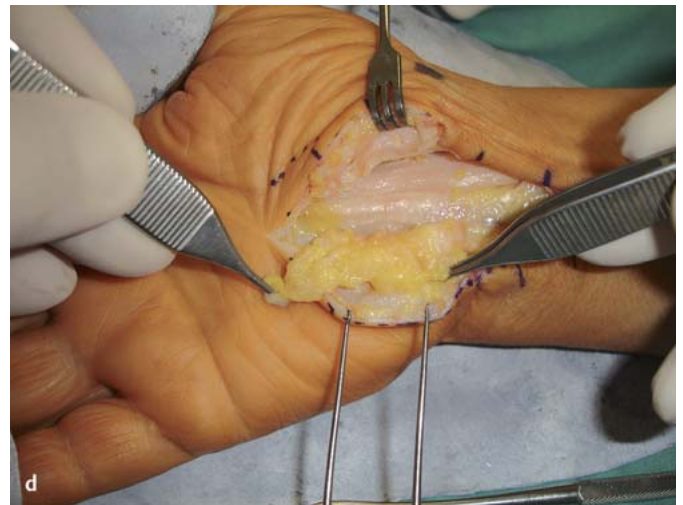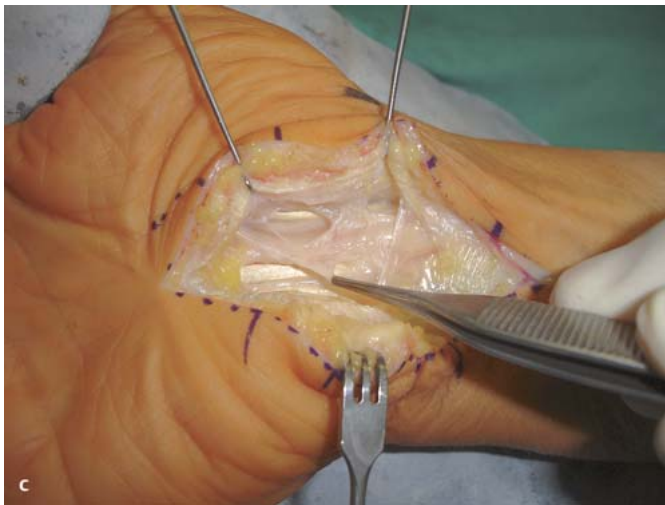
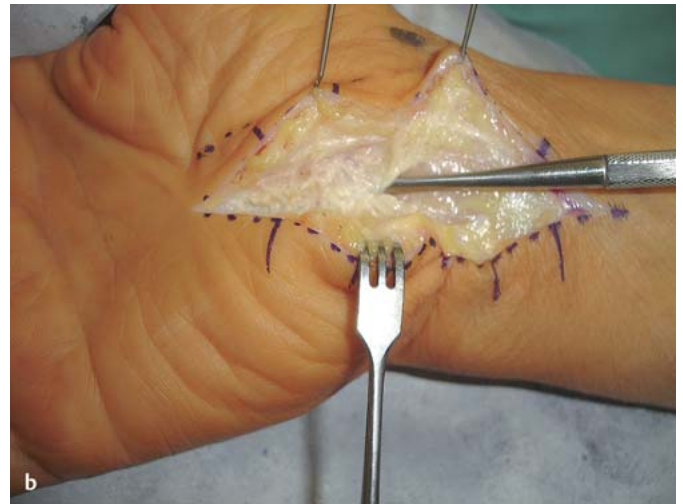
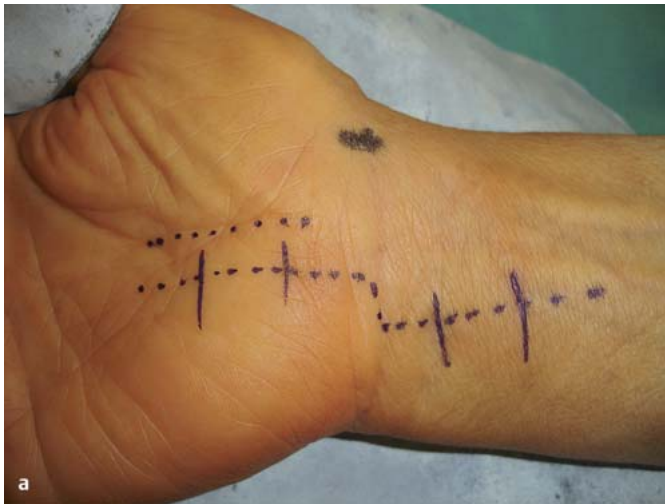carpal tunnel. In this way the median nerve is protected from further palmar displacement and cushioned by a sufficiently thick fatty layer against the palm's hollowed arc (Fig. 1e). The nerve is now in a position to slide freely in a longitude direction.

### Forearm radial artery flaps

The reverse island forearm radial artery flap is used the most in the treatment of hand pathologies that require tissue reintegration. The radial flaps can be classified on the basis of their composition as fascial, adipofascial, and fasciocutaneous [4, 15]. The surgery consists of harvesting the radial fascial or fasciocutaneous island reverse flap by sacrificing the radial artery in the proximal segment of the forearm. A preoperative Allen test must be performed to confirm the ulnar artery's patency and its capacity to supply blood to the hand [15]. The incision should widely expose the median nerve on the pre-existing scar. The incision is then directed radially, towards the flexor crease of the wrist and moves in a diagonal direction towards the radial aspect of the forearm. If intraoperative findings demonstrate severe median nerve scar entrapment, the surgeon should proceed with harvesting a reverse island forearm radial artery flap. To proceed with the reverse island fascial radial artery flap, a linear incision is made in a distal-proximal direction, extending proximally to within a few centimetres of the elbow flexion crease. The interval between the fat and the fascia must not be disrupted and carefully preserved since it contains the epifascial vascular plexus network and an adipose tissue layer. The fascia is incised at its periphery and dissected in a plane that lies immediately above the forearm muscle's epimysium and extends ulnarly, as well as radially, towards the radial artery septum. The fascial flap is fed by the radial artery and its dimensions are 5 cm in length and 4 cm in width. Once the flap has been raised, the radial artery and the venae comitantes are sectioned to the flap's proximal extremity (Fig. 2). The fascial flap is turned down distally and buried under the flexor carpi radialis muscle, in such a way that its gliding surfaces wrap around the median nerve in a dorso-palmar direction, enveloping its entire circumferential length within the carpal tunnel [20] (Fig. 3). Its pivot point is about 4 cm proximal to the radial styloid. The flap margins are sutured with 6/0 absorbable non-continuous sutures. The surgeon should suture the flap so that its borders slide towards the tunnel's ulnar side in order to exclude the possibility of adhesions forming between the three layers: epineurium, fascia, and skin. The tourniquet is then removed and the vitality of the flap can be determined once accurate haemostasis has been established.

This surgical technique needs to be modified in specific cases in which multiple neurolyses have been performed and the preoperative clinical exam indicates that the thenar and hypothenar eminence have become too close together due to a tenacious scar retraction. In such cases, the surgeon needs to harvest a reverse island fasciocutaneous radial artery flap. This method is comparable to the previously described technique, with the only difference being in the harvesting of an elliptical shaped antebrachial island skin flap that measures about 5 × 3 cm. It is slightly longer than the carpal tunnel's cutaneous area, therefore, it can be positioned between the thenar and hypothenar eminences, in order to avoid skin retraction recurrence in the palm thus resulting in median nerve compression. In addition, it can be used as a convenient indicator as to the flap's vitality [15]. The skin flap's ellip-





**Fig. 1 a to e** Clinical case. Female, 45 years old, with persistence of symptoms of CTS on the right wrist after OCTR. **a** Palm wrist skin incision according to Dellon and Chang [7], ulnarly to the scar of the previous. **b** Flexor retinaculum. **c** The scarred median nerve is adherent to the deep part of the flexor retinaculum. **d** The hypothenar fat-pad flap has been harvested from the ulnar side. **e** The hypothenar fat-pad flap is rotated to cover the median nerve.

tical axis will be situated exactly along the flap's long axis. It is useful for the surgeon to dissect a fascial flap that extends in a radial direction by a few centimetres, thus maintaining the cutaneous island slightly off centre on the fascial flap's ulnar side. In this way, the fascia can be evenly wrapped around the median nerve's entire circumference and at the same time guarantee that the suture margins fall on the tunnel's ulnar side, maintaining the skin island precisely in the interthenar zone (Fig. 4 a to h).

#### **Retrograde radial forearm flap**

The retrograde radial forearm flap is a distally based adipofascial flap that is distinguished from the reverse radial artery forearm flap since it can be harvested without having to sacrifice the radial artery [3,21].

The surgery begins by exposing the median nerve, respecting the same standard techniques that have already been described for harvesting the reverse fascial radial artery flap. The incision extends proximal to the wrist flexors, slightly deviating itself radially at the intersection with the palmaris brevis. It then continues in a straight line along the forearm's medial portion until it reaches the flap's pivot point (which is located about 4 cm from the radial styloid) and up until the proximal third of the forearm which is located a few centimetres from the elbow crease. The two flaps are cut out, respectively, ulnar and then radial, so that the antebrachial fascia is amply exposed and the epifascial surfaces are carefully preserved by maintaining a thin layer of adipose tissue. Since the dissected tissue is of minimal thickness it is compatible, on one hand, in facilitating flap gliding and on the other, for avoiding the presence of an excessive depression at the donor site. Therefore, a rectangular adipofascial flap can be harvested, the length of which is traced by two longitudinal ulnar and radial parallel incisions. It differs from the standard radial island fascial flap, since its diameters cover the entirely exposed antebrachial fascial surface and it contains all of the epifascial vascular network, which perfuses the flap both collaterally and distally. The width of the flap is compatible with the amount of surface coverage that is needed for it to be wrapped around the median nerve at the wrist and palm. The thickness of the dissection plane must always include adipofascial tissue in the incision in order to preserve the integrity of the adipofascial vessels. They collect together in the virtual space situated between the adipose tissue and fascia and assure that the flap is vascularised in a three-dimensional manner, passing over the forearm flexor muscles' anterior surface. As the flap is elevated, the radial artery is not transected; it is protected and remains intact below the flap. A few small perforating vessels coming off the radial artery to the fascia at the proximal and mid forearm level may be transected safely during elevation of the flap. It is imperative that particular attention is paid to respect and preserve the portion of the radial nerve that emerges from the ulnar border of the brachioradialis muscle border and the forearm's lateral cutaneous branch. The nerve must be identified when performing a proximal third fascial radial border incision, so that it is protected during the transverse incision of fascia, as well as to isolate it from the adipose tissue when cutting out the flap in a proximal distal direction. The retrograde radial flap's pivot point will be located slightly proximal to that of the standard one. The flap remains viable, being nourished by the radial artery's distal perforating vessels and its distal collateral circulation which is located just proximal to the wrist and flows in a retrograde fashion within the raised adipofascial flap. These vessels supply the adipofascial flap at about 5–8 cm from the wrist flexor crease. It is necessary to check the presence and integrity of the distal vessels once the flap has been harvested, in order to verify if they are sufficient in number for providing proper flap perfusion. The flap is then elevated and turned distally towards the carpal tunnel, assuring 90–180° of rotation, so that the gliding surface will be ample enough to wrap around the median nerve. The flap will be housed and sutured in the tunnel, analogous to that which has been previously described in the standard technique. The tourniquet is then removed and the vitality of the flap can be determined once accurate haemostasis has been established.

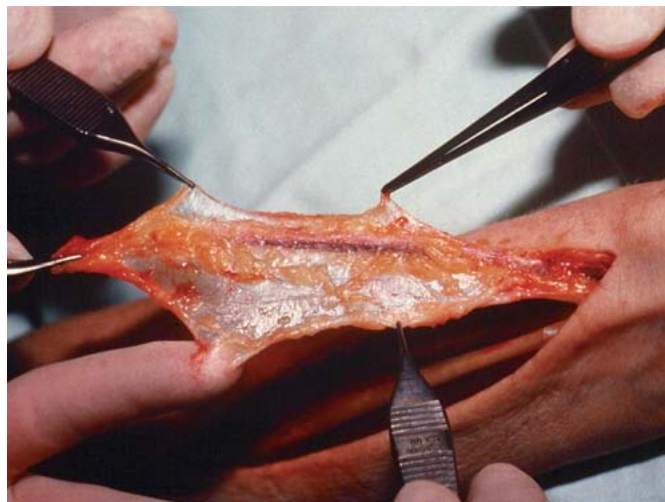
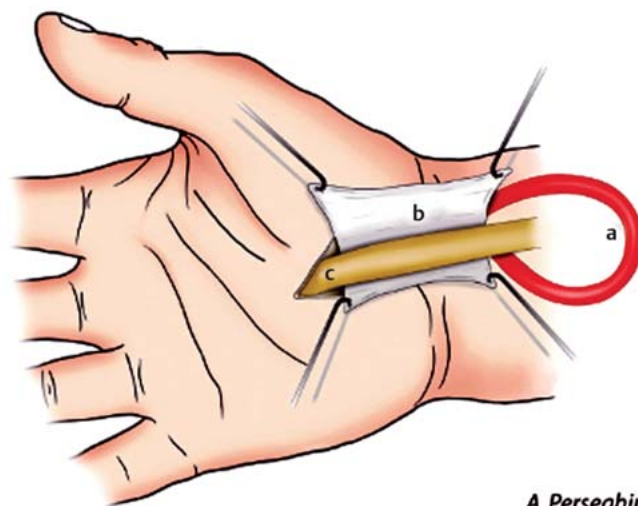


Fig. 2 The radial artery fascial flap raised from the forearm with the distal radial artery and venae comitantes intact distally and showing the fascia consistency and amplitude.



A. Perseghin

Fig. 3 Schematic drawing showing the technique of median nerve wrapping (permission granted for use by Verduci Publisher, Roma, Italy). The radial artery island fascial flap is rotated towards the carpal tunnel. The epifascial surface is circumferentially wrapped around the median nerve. (a) Radial artery, (b) radial forearm fascial flap, (c) scarred median nerve.

#### Forearm ulnar artery flap

The ulnar artery flap, described by Lovie et al. [12], is a fasciocutaneous flap overlying the proximal and central one third of the forearm along the course of the ulnar artery. It can be raised in a similar fashion to the radial artery flap. The ulnar artery flap has important advantages: the skin paddle is thinner than the radial equivalent, pliable, without adipose tissue, and virtually hairless. It is much more compatible with the thickness and skin type quality of the palm. Nevertheless, it should be stressed that the flap's mesenteric attachment to the ulnar artery is much more tenuous than the radial artery flap and consists of one or two small branches. The donor site is more acceptable because it offers better aesthetic results than the radial equivalent since it allows for an easier and less taut closure. The scar, which is positioned laterally, is less apparent and has a lower incidence of complications, such as hypertrophy and pain, whereas a skin



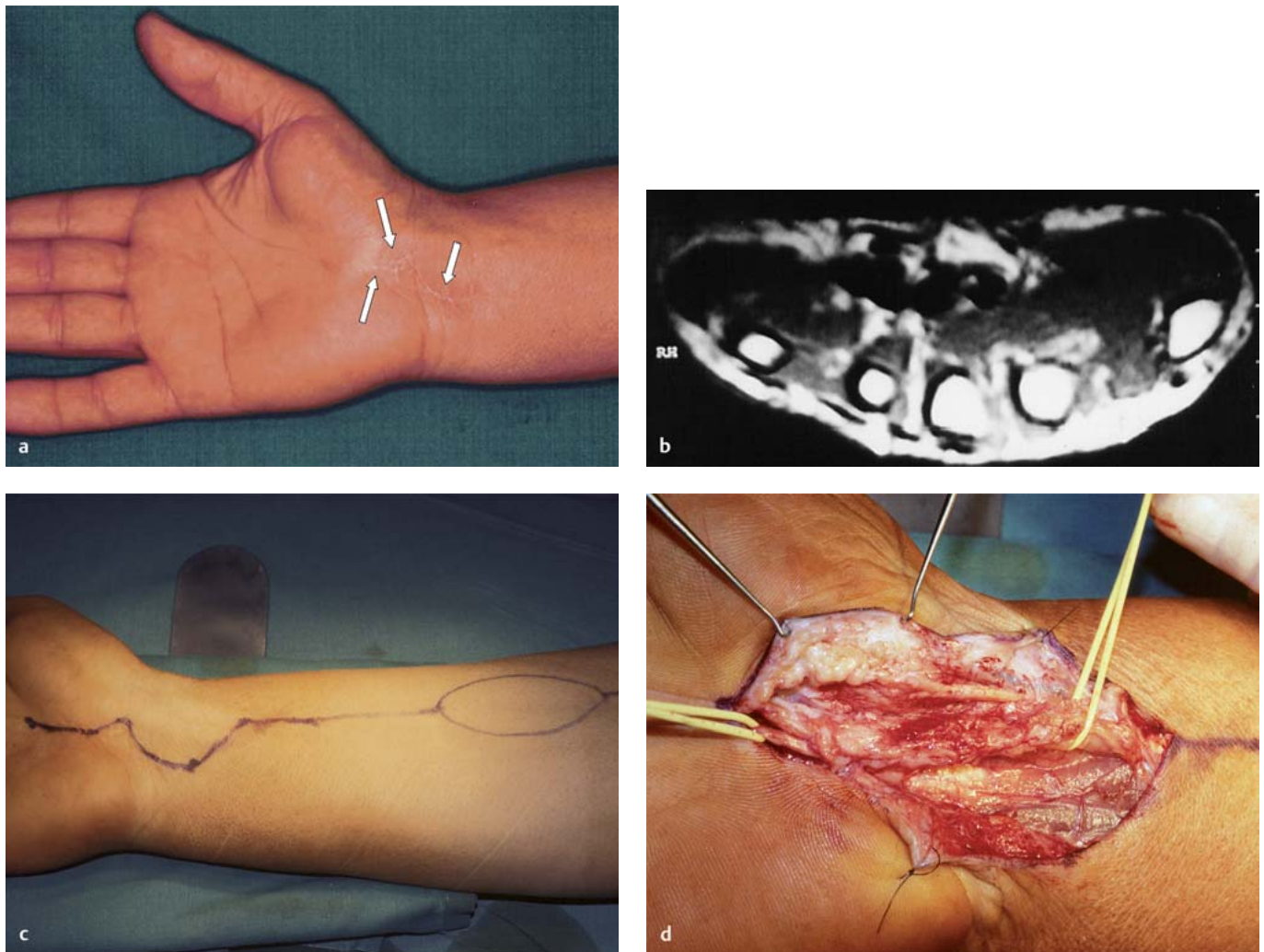


Fig. 4 a to d

graft easily roots itself to a well-padded muscular bed. The ulnar flap's rotation point is located more distally than that of the radial flap. It is located up by the palm and can totally compensate for its minor rotation arc, which is under anatomical obligation due to the position of the septal perforators. The sacrifice of the ulnar artery does not cause ulnar nerve devascularisation and does not cause symptomatic functional disturbances. Notwithstanding such advantages, many authors are reluctant to use this type of retrograde flap on the basis that there is a presumed dominance of the ulnar artery, with respect to the radial artery, in the blood supply of the hand.

The surgery consists of harvesting the reverse fascial or fasciocutaneous ulnar flap by sacrificing the ulnar artery in the forearm's proximal segment. A preoperative Allen test must be performed to confirm the patency of the radial artery and its capacity to supply blood to the hand [15]. The flap's longitudinal axis is centred over the course of the ulnar artery in the cleft between the flexor carpi ulnaris and the palmaris longus. The course of this longitudinal axial line is from the pisiform bone inferiorly, to the medial epicondyle superiorly. The skin and subcutaneous tissue are incised linearly along this axis until it reaches the forearm's proximal third in proximity to the elbow crease, and the antebrachial fascia is exposed on the forearm's ulnar side. The el-

liptically shaped fascial flap is elevated from the forearm's middle and proximal third junctions, where the septal perforators are usually found. The radial side of the fascial flap is first incised and the flap's radial half should be lifted up along the subfascial plane, passing into the intermuscular cleft between the flexor carpi ulnaris on the ulnar side and palmaris longus and flexor superficialis on the radial side. Once the ascending branches of the ulnar artery have been located, the flap's ulnar side is elevated and dissected from the subfascial plane up until the intermuscular septum, where it passes over the ulnar nerve. The dissection continues underneath the flap's mesenteric layer, progressing downwards to the ulnar vessels. After having verified that the vessel has been sectioned distal to the bifurcation of the common interosseous artery, a transversal incision is made on the fascia thus attaching and sectioning the ulnar artery to the flap's proximal extremity. The flap is then lifted in a distal direction by dissecting it out until it reaches the wrist's ulnar artery, which must be separated by the adjacent ulnar nerve, taking care to limit it as much as possible from being devascularised. Once the flap is rotated, it is used for reconstructing the median nerve's gliding system and for inter-thenar skin island coverage. This part of the surgical procedure is analogous to that which has been described for the radial flap (Fig. 5 a to g). The rotation arc of the ulnar artery flap is shorter than that of the radial artery

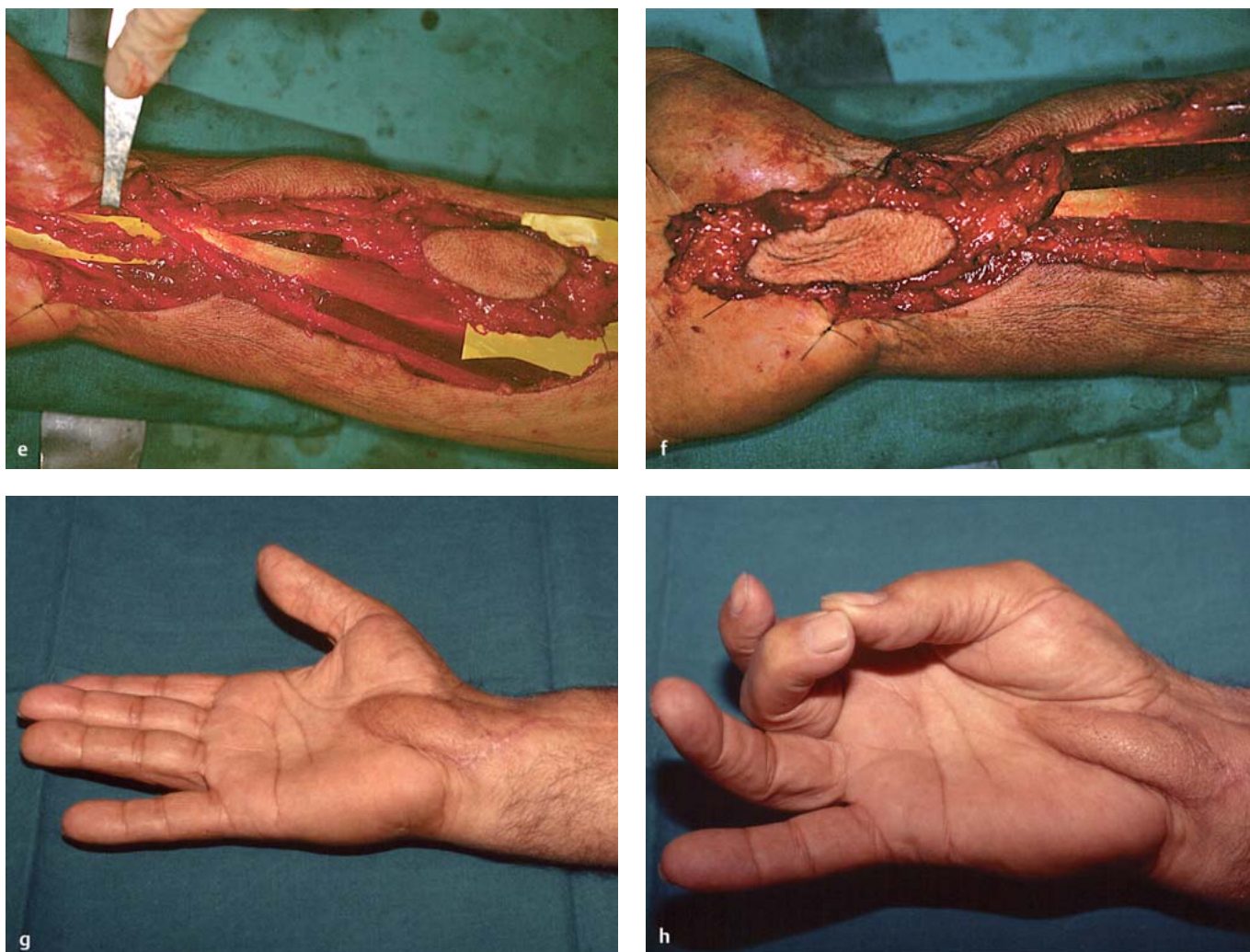


Fig. 4 **a** to **h** **a** Male, 55 years old, with residual scarring (three arrows) after three OCTR operations. **b** Preoperative MRI image showing the median nerve scar adhesions. **c** Preoperative procedure planning. **d** The median nerve after the external neurolysis: it is evident the intr fascicular scar tissue with interruption and dislocation of the nerve fasciculi. **e** The radial island fasciocutaneous flap is harvested and **(f)** transferred to cover the median nerve. **g, h** Functional results at long term follow-up.

flap. It is determined by the location of the common interosseous artery bifurcation. In order to completely cover the median nerve, at the carpal tunnel level, the flap's pivot point can be distally displaced by extending dissection of the ulnar artery until the palm.

#### **Ulnar fasciocutaneous and fascial fat flap**

The ulnar artery flap, described by Becker and Gilbert [1], is a fasciocutaneous or fascial fat flap vascularised by the median branch of the cubital-dorsal artery, which arises constantly (99% of cases) at the forearm from the ulnar artery between 2 and 5 cm proximally to the pisiform bone, then reaches the deep face of the flexor carpi ulnaris tendon, where it divides into two subcutaneous branches defined as the descending and ascending branches. The flap is vascularised by the ascending branch that, lying under the antebrachial fascia, goes towards the medial epicondyle and vascularises the ulnar side of the antebrachial fascia and the corresponding skin for a maximum extension of 20 cm in length and 9 cm in width, allowing easy and safe dissection of a subcutaneous retrograde fascial fat flap 13–14 cm long and 3 cm wide. The distal point of rotation, between 2 and 5 cm proximally

to the pisiform, permits the flap to reach the distal side of the carpal tunnel covering completely the median nerve with a soft fat tissue. The arc of rotation of this reverse pedicle flap is complete. The fascial fat flap dissection will be described but the fasciocutaneous flap can be also elevated in the same way including the skin over the fascial fat tissue.

The incision is outlined longitudinally on the skin overlying the ulnar artery and extends proximally up to the mid third of the forearm. The pisiform bone is marked as the pivot point and the incision length is 15 cm. A sharp dissection is done just underneath the subdermal plexus between the skin and the underlying adipose surface, thus exposing an adipose plane which has the dimensions of 13–14 cm in length and 4–5 cm in width (Fig. 6 **a** to **f**). Care must be taken to avoid harvesting too thin a cutaneous flap, so that the skin does not become devascularised. Flap dissection is started proximally at the forearm's distal border: the adipose tissue and the underlying antebrachial fascia are incised transversally in a plane just above the forearm muscles' epimysium. The incision continues in both a radial and ulnar distal direction, elevating a flap that is 3 cm in width. The



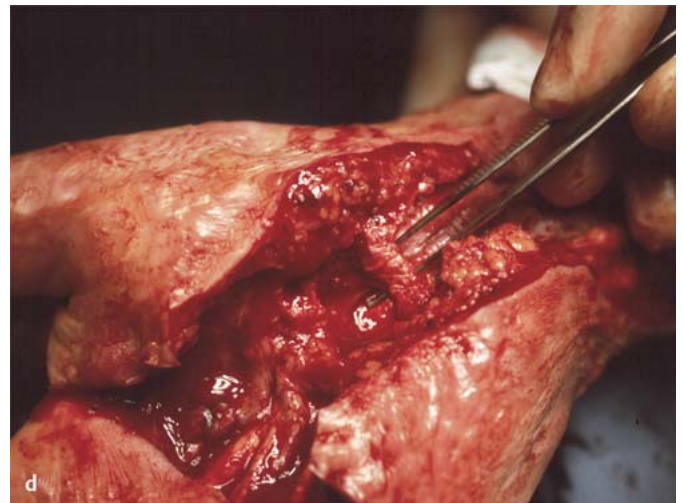
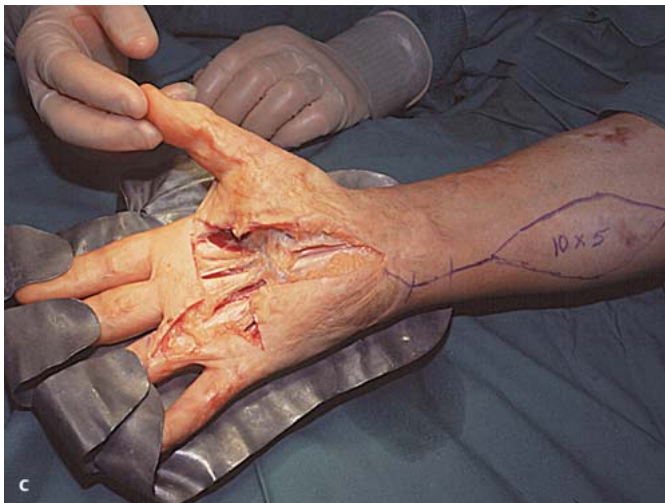
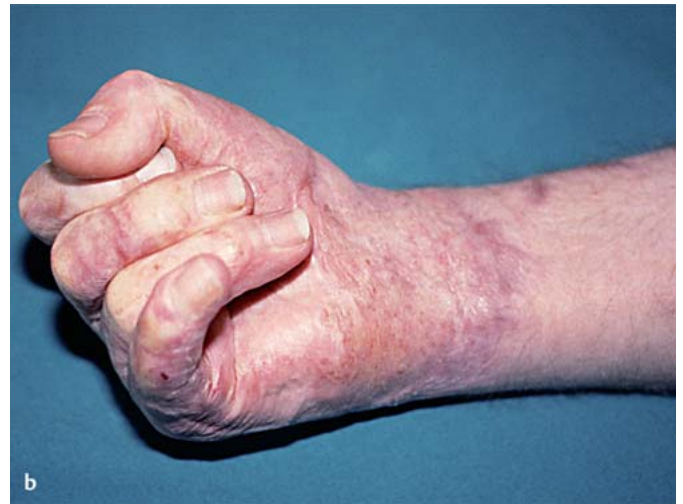
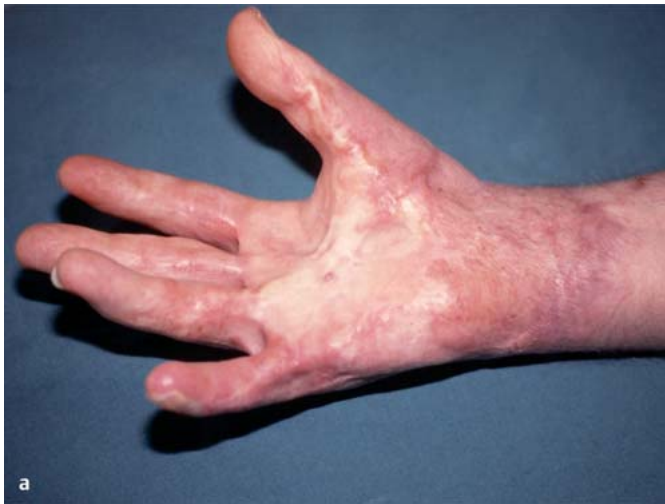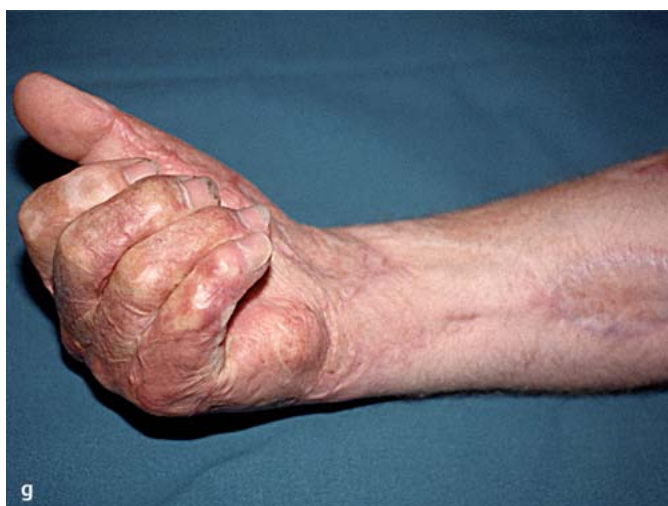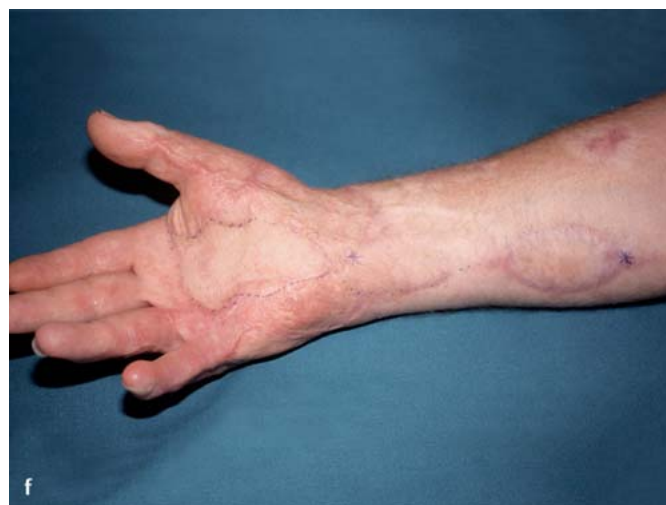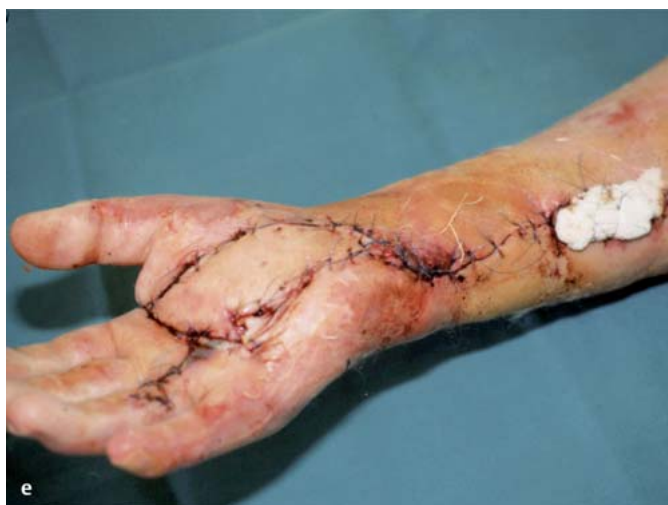Fig. 5 a to d

flap's distal deep plane dissection identifies the ulnar neurovascular bundle and numerous small vascular branches extending from the ulnar vessels to the fascio-adipose flap. These vessels must be cauterised. Division and elevation of the flap are carefully performed up until the flap's pivot point is reached (2–5 cm proximal to the pisiform bone where the vascular pedicle can be identified). The fascial fat flap that has been obtained measures 3 cm in width and 13–14 cm in length. At about 2.5 cm proximal to the flap's rotational point, it may be turned in a distal direction on top of the median nerve up until it reaches the distal part of the carpal tunnel. It is then passed subcutaneously under a small skin bridge that separates the ulnar from the carpal incision. This manoeuvre is done so that the median nerve is covered for its entire length within the carpal tunnel. Mattress sutures are placed through the radial and ulnar walls of the tunnel and through the flap's distal edge, thereby placing it over the nerve. The cutaneous tissue over the donor flap is closed primarily. Primary skin closure in the carpal region is possible despite the flap's mild bulging. The skin of the donor site can be closed primarily also when the fasciocutaneous flap version is used. The skin of the fasciocutaneous flap is modelled over the axis of the interthenar zone to replace the removed scar skin of previous surgery. A light transverse compression bandage is placed over the flap.

#### **Posterior interosseous flap**

This flap has been described by Zancolli and Angrigiani [23,24] and, furthermore, specifically elaborated on by numerous authors [15] regarding its vascular anatomy and its multiple applications. This flap has been accepted with enthusiasm for its use in traumatic hand treatments, since it holds the same applicative advantages as that of the other island flaps harvested from the forearm's anterior side. It differs in that it has the enormous advantage of not sacrificing a major artery to the hand. The flap is centred on a line between the lateral epicondyle of the humerus and the distal radial ulnar joint with the forearm in a position of full pronation. The flap's base is located 4–6 cm inferior to the lateral epicondyle and a point approximately 9 cm distal to the lateral epicondyle marks the centre of the skin island. At the inferior edge of the skin island margin, a vertical incision is made and extended to the level of the distal radial ulnar joint in order to permit the elevation of the vascular pedicle to its pivot point. At the wrist, the extensor carpi ulnaris and the extensor digiti minimi muscles are identified and separated in order to isolate the posterior interosseous artery and the associated venae comitantes in its most distal tract on the dorsal surface of the interosseous membrane. Care is required to show the distal anastomosis with the anterior interosseous artery. The incision is extended proximally through the flap's radial margin and deep fas-

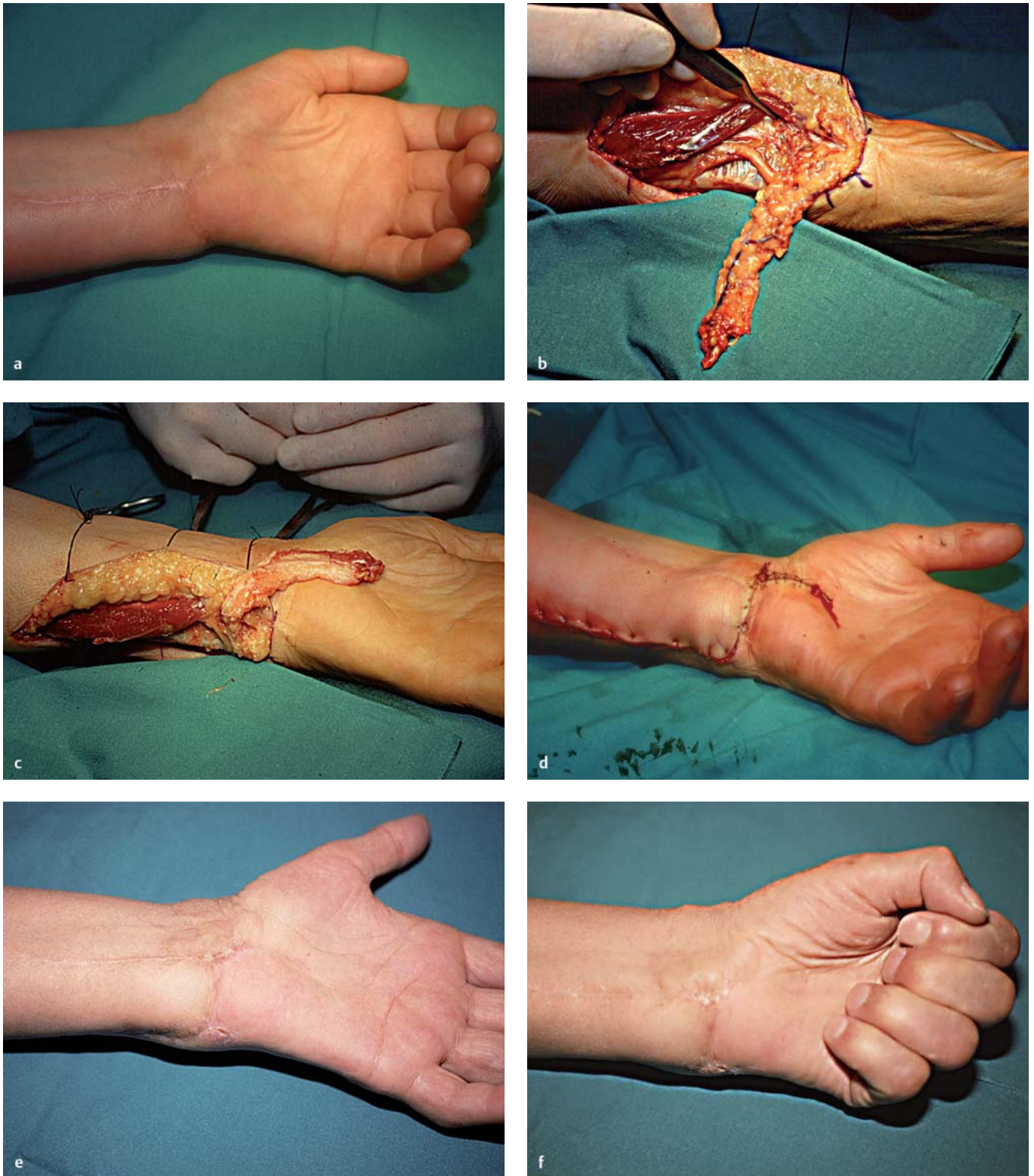




**Fig. 5a to g** **a,b** Preoperative clinical aspect of the right hand of patient (41 years old) with recurrence of CTS after thermal burn to the palm and wrist. **c** Cross incision of the palm with extension incision of the wrist and forearm. The median nerve was detached from the surrounding scar tissue and the flexor retinaculum proved to be absent. **d** Reconstruction of the flexor retinaculum according to Lluch's technique [10]. **e** Postoperative result of the distally based forearm ulnar artery flap rotated onto the palm: the fascia covers the median nerve and the island skin has reconstructed the palm. **f,g** Functional result at long-term follow-up.

cia to the superficial dorsal forearm extensor musculature. The flap is dissected out until it includes the fascia that covers the extensor digiti communis. The fascia is sutured to the skin so that the flap does not come apart. By proceeding in this manner it is possible to adapt the flap dissection based on the location of the underlying perforators and by modifying the flap's elevation in a distal and proximal direction so that its dissection is extended and includes at least one or two large perforators. Once the position of the perforators has been identified, the skin island is incised on the ulnar side through the deep fascia to the underlying extensor carpi ulnaris and extensor digiti minimi muscle bellies, until the muscle septum is completely exposed. At the distal flap edge, which is located in the proximal forearm, these muscle bellies are separated in order to inspect the underlying supinator muscle. Immediately distal and deep to the supinator muscle the posterior interosseous artery and associated venae comitantes are identified, tied, and sectioned, immediately after the origin of the large proximal perforator so it is included within the flap. The adjacent posterior interosseous nerve is identified too, and preserved. If the motor branch to the extensor carpi ulnaris from the deep radial nerve crosses superficially to the posterior interosseous artery, it is necessary to tie and divide the vascular pedicle distal to this motor branch. If an exclusively fascial flap has been dissected out, the cutaneous incision should be

made along the flap axis exposing the fascia, by adequately elevating the two radial and ulnar cutaneous flaps, then the trans-fascial incision and the pedicle dissection follow the previously described techniques. The flap dissection is completed in a proximal-distal direction elevating the septum extending between the extensor carpi ulnaris and extensor digiti minimi muscle and the overlying deep fascia so that it includes the posterior interosseous artery and its septal ascending branches. At the forearm's distal third, the pedicle is usually wrapped in an osteofibrous sheath which is adherent to the ulna's periosteum. Care is required to complete the dissection, preserving the vascular pedicle, and to avoid the interruption of the T-shaped distal anastomosis with the anterior interosseous artery. It is an important anatomical landmark of the flap's pivot point because of its important role in perfusing the flap's vascular pedicle. The flap is ready for transposition to the carpal region, or through a subcutaneous tunnel which has an adequate width and accurate haemostasis, or in an open surgical field by incising the skin at the ulnar bridge in a dorso-palmar and also a proximo-distal direction (Fig. 7a to f). The exposure of the median nerve at the carpal tunnel and its entire circumferential wrapping is done using a standard technique. However, this technique must always take into account the dimensional limitations of the posterior flap with respect to the radial artery or ulnar artery flap, since it has



**Fig. 6a to f** **a** Left hand of patient affected by median nerve paralysis after CTR and surgery for ganglia removal from the palmar ulnar DRUJ. **b** The Becker-Gilbert fascial flap was harvested and **(c)** turned distally to cover the median nerve. **d** Immediate postoperative result. **e, f** Clinical result at the long-term follow-up.

an inferior amount of fascia surface that is available for median nerve wrapping and an inferior distal extension for the length of the nerve.

#### **Postoperative treatment and rehabilitation**

Drainage is always used in order to prevent the formation of a haematoma and is removed during the second postoperative day. The wrist is splinted in slight extension with the fingers free for immediate postoperative motion. The splint is removed after 7 to 15 days depending upon the type of flap that has been used.



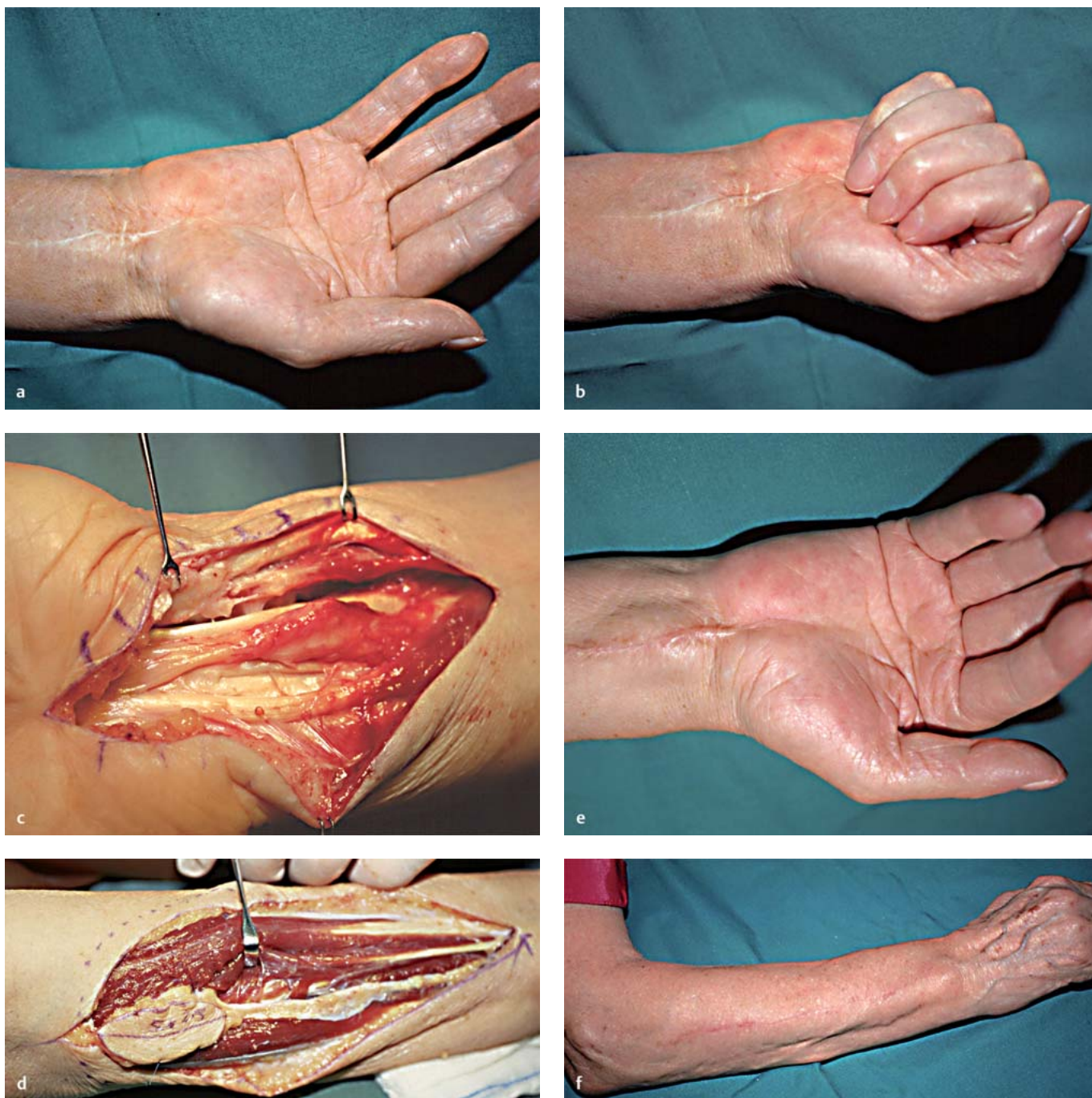

Fig. 7 **a** to **f** **a, b** Patient, 66 years old, with her right hand affected by median nerve lesion after OCTR. Patient was operated twice for CTS. **c** The median nerve was damaged proximally to the carpal tunnel. **d** The posterior interosseous fasciocutaneous island flap is isolated from the dorsum of the forearm. **e** Only the fascial island flap was rotated on the palmar wrist to cover the median nerve because the skin remained avascular. **f** Clinical result at the follow-up showing the little bulging over the median nerve at the palmar wrist and the donor site.

Once the splint is removed, a rehabilitation programme is initiated which consists of active and passive wrist mobilisation, gentle scar massage, and a scar desensitisation programme.

## Results

Twenty-five patients were evaluated after a mean follow-up of 51 months (12 to 168 months).

The pain evaluation showed an improvement passing from a mean value of 9 to 4. However, the best results were for the patients in which the median nerve was undamaged (mean VAS = 1).

Postoperative sensory and motor evaluation demonstrated that the less the nerve was damaged, the more were the symptoms improved. Postoperative neurophysiological examinations (EMG) showed the same tendency.



Tab. 2 Clinical results according to the flaps used

Type of flap	n	Excellent	Good	Fair
Hypothenar fat flap	19	11	7	1
Forearm radial artery flap	2		2	
Forearm ulnar artery flap	2		2	
Ulnar fascial-fat flap	1			1
Posterior interosseous flap	1		1	
Total	25	11	12	2

According to the assessment of the evaluation parameters that is reported in Table 1, the results were grouped as follows: eleven patients obtained excellent results, reporting both complete disappearance of their symptoms and full return to work, in addition to full recovery of their finger tip discrimination capacity. Good results were obtained in twelve of the 25 patients who were treated. These results underline that return of hand function is probable but it is preceded by a period of spontaneous intermittent painful finger paraesthesia and wrist scar tenderness that was easily evoked by even the lightest touch. In two patients fair results were obtained and were characterised by slight symptom intensity reduction to which they learned to adapt. Nevertheless, some of these patients developed an evident psychological intolerance and a chronic pathological state where they reported no periods of well-being. Specifically, one of these patients complained prior to the initial surgery of a very severe pain that was causing him to go into a state of deep depression and led him to an attempted suicide.

Clinical results according to the flaps used are reported in Table 2.

No comparison was possible between the group of patients treated with a fat flap and the group in which the more complex flaps were used (radial, ulnar, and posterior interosseous flaps) because the patients in the later group were few in number and had more severe median nerve damage. However, some considerations can be made: the most frequently used flap has been the fat flap described by Strickland et al. [19]. It was used in 19 cases, in which adhesions had anchored down the median nerve to the retinaculum scar. It was also used in a case in which the median nerve was grafted for partial injury, in association to median nerve vein wrapping [18] for tenacious adhesions around its distal portion (one case). In all the cases, the fat flap covered the median nerve from the distal wrist crease to the palm (distally to the distal border of the retinaculum). No complications were detected. The fasciocutaneous flaps were used in six cases: forearm radial artery flaps (n=2), forearm ulnar artery flap (n=2), ulnar fascial fat flap, and posterior interosseous fascial flap, respectively, in one case each. The ulnar flap was used to replace a symptomatic CTS burn patient's dystrophic palmar skin. The flexor retinaculum was also reconstructed in this patient by using the palmaris brevis tendon as suggested by Lluch [10]. In the second case a fascial ulnar flap was used. The posterior interosseous fascial flap was used to cover a median nerve that had been damaged proximal to the distal wrist crease (Fig. 7a to f).

In most of the cases, the patients' symptoms showed an improvement. The level of symptom improvement was correlated to the amount of median nerve damage present. In the patients whose median nerve was only involved in the scar, nocturnal symptoms were the first to disappear followed by the diurnal paraesthesia and sensory and motor deficits. In the first group, in which the fat flaps were used to protect the median nerve affected only by adhesions, the symptoms improved more than in the second group in which the nerve was damaged (internal fibrosis or partial median nerve injury). The case in which the median nerve was damaged and covered by the hypothenar fat flap showed the same results as that of the second group.

Patients with palmar and wrist skin replacement by the fasciocutaneous flap (n=3) were satisfied with their result in terms of decreased pain and flattened palms with thumb supination. However, complete recovery of symptoms was never completely reached due to major median nerve involvement. Moreover, the donor sites, in which the fasciocutaneous flaps were harvested, were not completely symptom-free. Patients reported new symptoms, the majority occurring in the palmar radial forearm area from the radial artery flap. Patients who were operated on by using an ulnar artery flap, the fasciocutaneous fat flap and posterior interosseous fascial island flap did not complain of new symptoms at the donor site.

Worst results (n=2) occurred in those patients where there was a partial median nerve injury and nerve grafts were performed.

## Discussion

Recurrent CTS is frequently reported in the literature with an incidence that ranges from 0.3% to 20% in treated cases [15].

Particularly, persistent CTS is characterised by unrelieved or transient relief of symptoms and is most often due to an incomplete transverse carpal ligament sectioning. The patient tends to complain of postoperative finger paraesthesia, hypaesthesia, and/or sharp pain. These symptoms are highly associated with positive electromyography results for median nerve compression. In these cases, a revised carpal tunnel surgery with a correct CTS release enables recovery. The latter cases correspond to the majority of our re-operated cases (67%).

Recurrent CTS, characterised by the return of symptoms after three months from the time of surgery, is usually associated with fibrous proliferation within the carpal tunnel and median nerve scar adhesion on the transverse carpal ligament's radial half. In such cases, the surgical treatment requires a wide exposure of the median nerve, the nerve's dissection from its surrounding scar tissue (particularly at the undersurface of the transverse carpal ligament's radial side) and a flap transposition over the injured median nerve to protect it from the formation of new scar adhesions and to prevent re-innervation of the overlying scarred and denervated skin. This will markedly reduce the possibility of cutaneous hyperalgesia from occurring. Usually, the authors use the hypothenar fat-pad flap to cover the median nerve from the proximal wrist crease to the palm, while the pronator quadratus flap or the palmaris brevis flap can be used to cover the nerve at

a more proximal level. Sometimes the intraoperative findings demonstrate a severe circumferential median nerve scar entrapment. After multiple neurolysis, median nerve compression and the nerve scar entrapment are associated with the formation of fibrotic endoneural scarring that causes severe structural suffering: torsion and amputation of the fascicles and amputation of the vessels. These repetitive and chronic injuries determine an increase in endoneural fluid pressure [15] (“miniature compartment syndrome” [13]) and they lead to severe ischaemic nerve injury, which is associated with a severe and pharmaco-resistant pain syndrome. In such cases, the simple concept of covering and protecting the injured nerve from the surrounding scar tissue in order to prevent new adhesions from occurring after a superficial neurolysis, is not enough to interrupt the severe pain syndrome. The scarred median nerve requires “interfascicular neurolysis”, with microneurosurgical techniques, in order to completely detach the median nerve fibres from their surrounding scar tissue and reconstruct the nerve’s entire gliding mechanism by means of a tissue flap, which is able to easily reach the median nerve and circumferentially wrap itself around the entire length of the nerve in the carpal tunnel. These flaps are also useful to cover or wrap the median nerve in cases in which nerve grafts have been used for partial or complete nerve injuries. This group corresponds to the patients with new symptoms onset.

The most frequent flap used in our series has been the hypothenar fat flap. It was chosen for its vicinity to the median nerve that it must cover. We suggest its use as first choice when the median nerve result is affected by minor involvement in the scar of previous surgery. If the median nerve result is involved by major and tenacious adhesences we suggest the use of the more important flaps.

The easiest and most useful flap to perform is the reverse radial artery fascial flap. It not only separates the median nerve from its surrounding scar tissue, but also allows for the nerve to glide pain-free within the canal and to revascularise itself by neo-angiogenesis. The disadvantage of using this flap is that it necessitates a long scar and the radial artery must be sacrificed. None of our patients complained of post-surgical flap morbidity (cold intolerance, intermittent pain). However, the patients did report skin discomfort in the radial forearm region.

In cases in which it is necessary to substitute dystrophic cutaneous skin due to repetitive CTS surgeries, a hairless fasciocutaneous flap such as an ulnar flap or a Becker-Gilbert flap is indicated. These flaps have been demonstrated to render both positive functional and aesthetic results.

The results that we have collected from median nerve gliding mechanism reconstruction in recurrent CTS are certainly encouraging in this small selected group of patients. Nevertheless, this technique is much more complex than the simple CTR and can be the source of some patients’ postoperative discomfort, even slightly different from that which is expected. It is imperative that the patient is preoperatively informed of the surgical procedure and that a clinical evaluation distinguishes between a persistent CTS resulting from an incorrect surgical procedure and a recurrent CTS, as well as from cases in which scarring has completely obliterated the nerve’s gliding capacity. The surgeon

should recognise preoperatively the ideal candidate for this treatment. In our opinion, the patient’s type of pain is the fundamental symptom that helps the surgeon to make the differential diagnosis and to distinguish between different pathological situations. Only after a thorough evaluation has been performed and the differential diagnosis has been made can the correct reconstructive surgery be scheduled.

## Conclusion

Clinical results of protective coverage of the median nerve after failure of CTR and/or unsuccessful reoperations are not always constant. From the present study it is evident that the median nerve damage affects the result: if the median nerve is shown to be damaged, protective coverage of it by flaps cannot give a favourable result in term of recovery of sensory and motor deficits. However, the protection of the nerve can reduce painful symptoms even if it does not permit the return to a painless condition.

Moreover, the most common flap we can use in such conditions is the hypothenar fascial fat flap. It is very easy to elevate from the ulnar border of the canal and permits to cover all the median nerve along the carpal canal. Important flaps are needed when the nerve shows to be more involved in the scar or damaged. These flaps are more complex consisting in fascial or fasciocutaneous flaps harvesting from the palmar or dorsal forearm. They can cover the nerve, giving both a better nerve protection and gliding tissue than the hypothenar fat flap. However, the donor sites have demonstrated to leave some discomfort that must be taken into consideration before making the choice of the flap.

## References

- 1 Becker C, Gilbert A: The ulnar flap. In: Tubiana R (Ed): *The Hand*. Philadelphia: Saunders, 1988: 149–151
- 2 Bedeschi P: Carpal tunnel syndrome surgical complications. In: Luchetti R, Amadio P (Eds): *Carpal Tunnel Syndrome*. Berlin: Springer, 2006: 269–289
- 3 Braun RM, Rechner M, Neill Cage DJ et al.: The retrograde radial fascial forearm flap: Surgical rationale, technique, and clinical application. *J Hand Surg [Am]* 1995; 20: 915–922
- 4 Chang B, Dellon AL: Surgical management of recurrent carpal tunnel syndrome. *J Hand Surg [Br]* 1993; 18: 467–470
- 5 Chang SM: The distally based radial forearm fascial flap. *Plast Reconstr Surg* 1990; 85: 150–151
- 6 Dahlin LB, Lekholm C, Kardum P, Holmberg J: Coverage of the median nerve with free and pedicled flaps for the treatment of recurrent severe carpal tunnel syndrome. *Scand J Plast Reconstr Surg Hand Surg* 2002; 36: 172–176
- 7 Dellon AL, Chang BW: An alternative incision for approaching recurrent median nerve compression at the wrist. *Plast Reconstr Surg* 1992; 89: 576–578
- 8 Duclos L, Sokolow C: Management of true recurrent carpal tunnel syndrome: Is it worthwhile to bring vascularised tissue? *Chir Main* 1998; 17: 113–117
- 9 Frank U, Giunta R, Krimmer H, Lanz U: Neueinbettung des N. medianus nach Vernarbung im Karpalkanal mit der Hypothenar-Fettgewebslappenplastik. *Handchir Mikrochir Plast Chir* 1999; 31: 317–322
- 10 Lluch A: Reconstruction of the flexor retinaculum. In: Luchetti R, Amadio P (Eds): *Carpal Tunnel Syndrome*. Berlin: Springer, 2006: 226–238

- <sup>11</sup> Loick J, Joosten U, Lucke R: Einsatz von oxidiertem, regeneriertem Zellulose zur Rezidivprophylaxe bei der chirurgischen Therapie des Karpaltunnelsyndroms. *Handchir Mikrochir Plast Chir* 1997; 29: 209–213
- <sup>12</sup> Lovie MG, Juncan GM, Glasson JW: Ulnar artery forearm free flap. *Br J Plast Surg* 1984; 37: 486–492
- <sup>13</sup> Lundborg G, Myers R, Powell H: Nerve compression injury and increased endoneurial fluid pressure: A “miniature compartment syndrome.” *J Neurol Neurosurg Psychiatry* 1983; 46: 1119–1124
- <sup>14</sup> Mackinnon SE: Secondary carpal tunnel surgery. *Neurosurg Clin N Amer* 1991; 2: 75–91
- <sup>15</sup> Riccio M, Bertani A, Morrison WA: Reverse island forearm flaps for the coverage of the median nerve in recurrent carpal tunnel syndrome. In: Luchetti R, Amadio P (Eds): *Carpal Tunnel Syndrome*. Berlin: Springer, 2006: 343–360
- <sup>16</sup> Rose EH, Norris MS, Kowalski TA et al.: Palmaris brevis turnover flap as an adjunct to internal neurolysis of the chronically scarred median nerve in recurrent carpal tunnel syndrome. *J Hand Surg [Am]* 1991; 16: 191–201
- <sup>17</sup> Spokevicius S, Kleinert HE: The abductor digiti minimi flap: Its use in revision carpal tunnel surgery. *Hand Clin* 1996; 12: 351–355
- <sup>18</sup> Sotereanos DG, Darlis NA: Vein wrapping of the median nerve. In: Luchetti R, Amadio P (Eds): *Carpal Tunnel Syndrome*. Berlin: Springer, 2006: 333–337
- <sup>19</sup> Strickland JW, Idler RS, Lourie GM, Plancher KD: The hypothenar fat pad flap for management of recalcitrant carpal tunnel syndrome. *J Hand Surg [Am]* 1996; 21: 840–848
- <sup>20</sup> Tham SKY, Ireland DCR, Riccio M et al.: Reverse radial artery fascial flap: A treatment for the chronically scarred median nerve in recurrent carpal tunnel syndrome. *J Hand Surg [Am]* 1996; 21: 849–854
- <sup>21</sup> Weinzweig N, Chen L, Chen ZW: The distally based radial forearm fasciocutaneous flap with preservation of the radial artery: An anatomic and clinical approach. *Plast Reconstr Surg* 1994; 94: 675–683
- <sup>22</sup> Wulle C: The synovial flap as treatment of the recurrent carpal tunnel syndrome. *Hand Clin* 1996; 12: 379–388
- <sup>23</sup> Zancolli EA, Angrigiani C: Colgajo dorsal de antebrazo (“on isola”) (Pediculo de vasos interosseoos posteriores). *Rev Assoc Arg Orthop Traumatol* 1986; 51: 161–168
- <sup>24</sup> Zancolli EA, Angrigiani C: Posterior interosseous island forearm flap. *J Hand Surg [Br]* 1988; 13: 130–135